



Alopecia in a Patient with Systemic Sclerosis

Ru Dai and Jisu Chen*

Department of Dermatology, Zhejiang University School of Medicine, Second Affiliated Hospital, P.R. China

Keywords

Alopecia; Digital image; Systemic sclerosis

Clinical Image

A 55-year-old woman presented to the dermatology department with a 10-year-history of hard and painful hands that progressively worsened over 2 months. Raynaud's phenomenon was seen after her hands were exposed to cold.

Physical examination revealed stiffness of the skin on her hands, forearms and face (Panel A), as well as ulcerations in the fingertips (Panel B). Marked alopecia with coarse hair was observed on the scalp (Panel C). The antinuclear antibody titer was 1:160. High-resolution chest computed tomography revealed pulmonary interstitial changes. A clinical diagnosis of Systemic Sclerosis (SSc) was made. We initiated treatment with calcium channel blocker, antiplatelet agents and intravenous Epoprostenol therapy. Oral mycophenolate mofetil daily was also used for treatment of interstitial lung disease. Diffuse hair loss was uncommon in patients with SSc [1], while alopecia areata and coarse hair are relatively common hair manifestations among patients with SSc [2]. It is important for physicians to aware that alopecia might indicate a diagnosis of SSc.

Key Message: Patient with Systemic Sclerosis can present as diffuse hair loss.

Author Contributions

R.D and J.C. was responsible for manuscript preparation and final approval of the paper.

Funding

Natural Science Foundation of Zhejiang province (LQ20H110002).

OPEN ACCESS

*Correspondence:

Jisu Chen, Department of Dermatology,
Zhejiang University School of
Medicine, Second Affiliated Hospital,
No. 88, Jiefang Road, Hangzhou,
Zhejiang, 310009, P.R. China, Tel:
+86-15982215914;

E-mail: chenjisu2835@163.com

Received Date: 09 Sep 2022

Accepted Date: 20 Sep 2022

Published Date: 22 Sep 2022

Citation:

Dai R, Chen J. Alopecia in a Patient
with Systemic Sclerosis. *Ann Clin Case
Rep.* 2022; 7: 2309.

ISSN: 2474-1655.

Copyright © 2022 Jisu Chen. This is
an open access article distributed under
the Creative Commons Attribution
License, which permits unrestricted
use, distribution, and reproduction in
any medium, provided the original work
is properly cited.

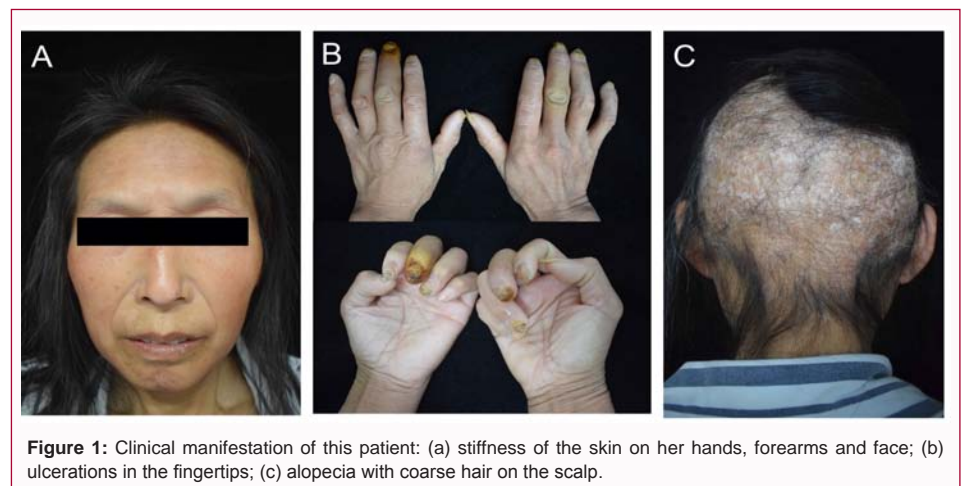


Figure 1: Clinical manifestation of this patient: (a) stiffness of the skin on her hands, forearms and face; (b) ulcerations in the fingertips; (c) alopecia with coarse hair on the scalp.

References

1. Denton CP, Khanna D. Systemic sclerosis. *Lancet.* 2017;390:1685-99.
2. Kridin K, Tzur Bitan D, Comaneshter D, Cohen AD. The prevalence of systemic sclerosis is increased among patients with alopecia areata: A population-based study. *Immunol Res.* 2019;67:368-72.