



A Rare Cause of Altered Mental Status: The Morel–lavallée Syndrome

Sarıcıcek BM¹, Aydın OF¹, Bıçakcı S¹, Gul E² and Guneysel O^{1*}

¹Lutfi Kırdar Kartal Education and Research Hospital, Emergency Medicine Clinic, Istanbul, Turkey

²Elaziğ Education and Research Hospital, Emergency Medicine Clinic, Elaziğ, Turkey

Abstract

Altered mental status is a common clinical condition with a wide and varied diagnosis. Morel–Lavallée Syndrome is rare but may be caused by a serious hemorrhage concluding with hemorrhagic shock. Hemorrhagic shock has occurred with altered mental status in a 76 year-old male patient with Morel-Lavallée Syndrome. Altered mental status occurred after hemorrhagic shock. The syndrome caused by post-traumatic hearing of the hypodermis from the underlying fascia. Physical examination, MRI and USG is the mainstay of diagnosis and treatment includes both surgical and minimally invasive modalities.

Introduction

Morel-Lavallée Syndrome is defined as the separation of skin and subcutaneous tissues from underlying fascia and results with a closed space in which haematoma and liquified fat tissues accumulate [1,2]. Morel-Lavallée Syndrome frequently appears as fluctuating fluid accumulation [1,2]. The lesion most frequently occurs in the greater trochanter, lowerback, knee and scapula [3]. Usually this is a sub cutaneous hematoma, but the hematoma can become so large that it seriously threatens hemorrhagic shock and the viability of the skin above [2]. Morel–Lavallée Syndrome is rare but may cause serious hemorrhage which can lead to a rapid reduction in blood volume [4]. Acute delirium, restlessness, disorientation, confusion and coma are caused by a decrease in cerebral perfusion pressure [5].

Here we report a case of Morel–Lavallée Syndrome that resulted in hemorrhagic shock with altered mental status.

Case Report

A 76 year old male presented with the acute onset of altered mental status. Family members reported that the patient was being less interactive and more anxious than usual. Vital signs at the time of admission were as follows; heart rate: 97/min, respiratory rate: 20/min, blood pressure: 140/90 mm-Hg and body temperature: 35.9°C. The blood glucose level was 320 mg/dl.

He was conscious and cooperated but was disoriented. His Glasgow Coma Scale score was 15. He was anxious and fidgety. Extremity examination revealed an ecchymosis along the lateral right femoral region, a soft, fluctuant mass just inferior to the ecchymosis and a short leg splint. No laceration or ulceration was present. Bullous lesions were present on the ecchymotic areas (Figure 1). The other system examinations were normal. Normal saline was the fluid of choice for initial therapy.

The patient was hospitalized for a talus fracture caused by the traffic accident 2 days before. Talus fracture was treated with a short leg splint. After two days, he was discharged and prescribed enoxaparin with an additional follow-up observation. Past medical history revealed that type-2 diabetes mellitus, chronic obstructive pulmonary disease and hypertension were present. His medication was β blocker.

Laboratory results were as follows; hemoglobin: 7.7g/dl, hematocrit: 22.5 (2 days before his hemoglobin level was 13.4 g/dl, hematocrit was 39.3), glucose: 336 mg/dl. Two units RBC preparations were immediately transfused. After transfusion, laboratory results were as follows: hemoglobin: 9 g/dl, hematocrit: 26.5. As soon as hemodynamic status had stabilized, thorax and abdominal computer tomography scans were performed. There were no pathologic findings.

OPEN ACCESS

*Correspondence:

Ozlem Guneysel, Lutfi Kırdar Kartal Education and Research Hospital, Emergency Medicine Clinic, Semsiz Denizer Cad. E-5 Karayolu Cevizli Mevkii 34890 Kartal / Istanbul, Turkey, Tel: +90 532 2211368; E-mail: guneysel@gmail.com

Received Date: 16 Apr 2016

Accepted Date: 02 Jun 2016

Published Date: 07 Jun 2016

Citation:

Sarıcıcek BM, Aydın OF, Bıçakcı S, Gul E, Guneysel O. A Rare Cause of Altered Mental Status: The Morel–lavallée Syndrome. *Ann Clin Case Rep.* 2016; 1: 1013.

Copyright © 2016 Guneysel O. This is an open access article distributed under the Creative Commons Attribution License, which permits unrestricted use, distribution, and reproduction in any medium, provided the original work is properly cited.

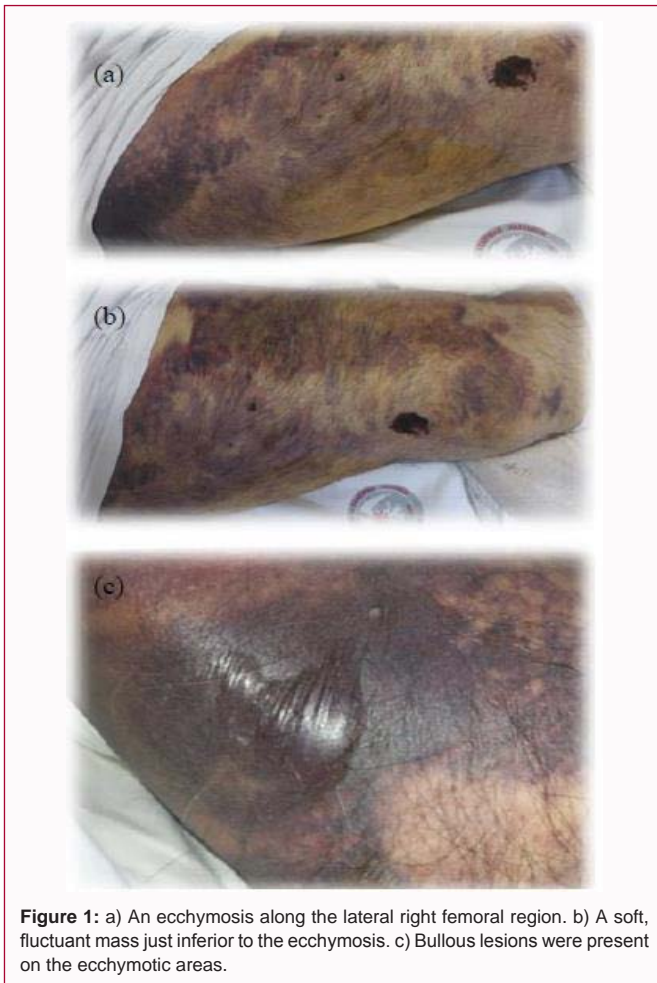


Figure 1: a) An ecchymosis along the lateral right femoral region. b) A soft, fluctuant mass just inferior to the ecchymosis. c) Bullous lesions were present on the ecchymotic areas.

The diagnosis was confirmed with magnetic resonance (MRI) which revealed that a well- marginated, T2 hyperintense, lentiform collection, between the sub cutaneous fat and fascia (Figure 2). The lesion measured 45 mm in dimension. The marrow signal of adjacent femur was normal. Surrounding muscular edema, sinus tracts or cutaneous defects were not present.

The patient was admitted to orthopedic surgery ward. The fracture was stabilized with a short leg splint. The hematoma was drained with a small incision and a compression bandage was applied. Damaged tissue debridement was performed after the patient was stabilized. A partial-thickness graft was applied. A drain was placed and delayed of a day. On the fifth day he was discharged with an additional follow-up observation.

Discussion

Morel- Lavallee Syndrome frequently appears as a fluctuating fluid accumulations [1]. In a multitrauma patient whose hemodynamic status was stabilised, a physical examination should be performed on an undressed patient and should begin with a quick head-to-toe inspection and all skin lesions on the whole body should be evaluated carefully for the diagnosis [1]. A fluctuating lesion and excessive skin mobility with manual examination was accepted as the finding. MRI and ultrasonography have been recommended to confirm the diagnosis [2].

Variable treatment options have been suggested for Morel-Lavallée syndrome. Wound drainage and a compression bandage was

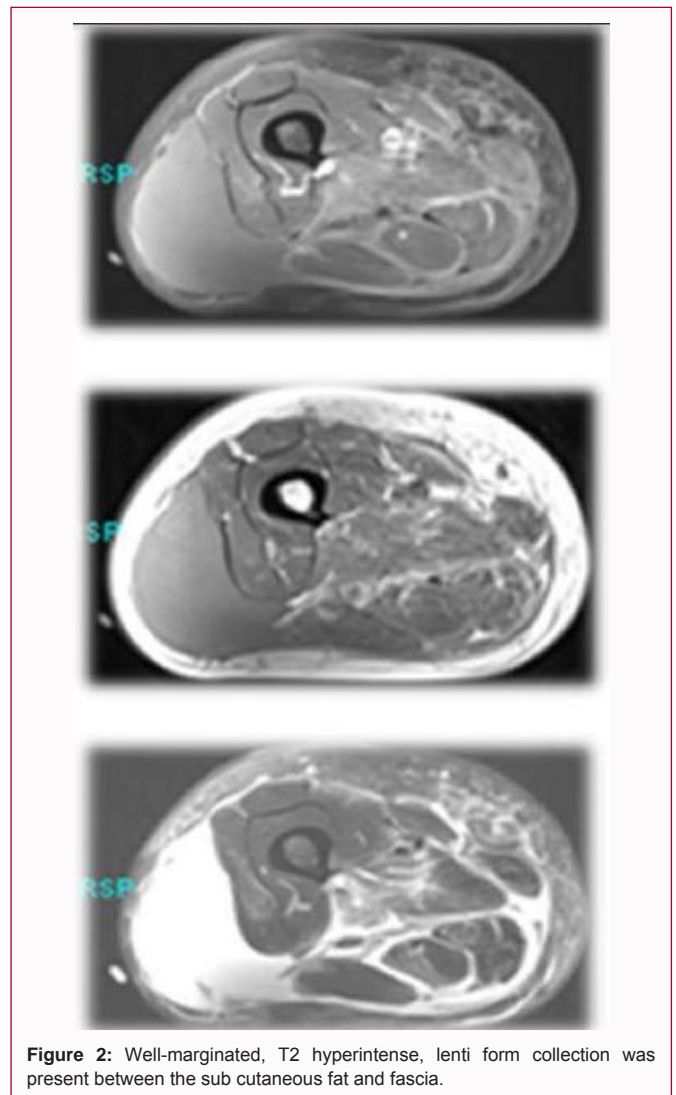


Figure 2: Well-margined, T2 hyperintense, lenti form collection was present between the sub cutaneous fat and fascia.

applied. Non-invasive treatment was performed with elastic bandages in closed degloving skin lesions [1]. The primary modality is to treat the soft-tissue problem at the same time the fracture is stabilized [2]. All of the treatment options have many complications, such as recurrence of the swelling, increased incidence of infection, skin necrosis etc.

Conclusion

Morel-Lavallée Syndrome is a rare cause of sub cutaneous swelling. Some times the disease can not be identified and may be fatal. Clinicians should be careful of the probable diagnosis.

Acknowledgement

I would like to thank Stephen Mason who were generous with his time and aid.

References

1. Harma A, Inan M, Ertem K. The Morel-Lavalleelesion: a conservative approach to closed degloving injuries. *Acta Orthop Traumatol Turc.* 2004; 38: 270-273.
2. Wood GW. General Principle of Fracture Treatment. Canale ST, Beaty JH. *Campbell's Operative Orthopaedics.* Philadelphia: Mosby Elsevier. 2008; 3018-3080.

3. Moriarty JM, Borrero CG, Kavanagh EC. A rare cause of calf swelling: the Morel-Lavallee syndrome. *Ir J MedSci.* 2011; 180: 265-268.
4. Jones AE, Kline JA. Shock. In: Marx JA (ed) *Rosen's Emergency Medicine.* MosbyElsevier, Philadelphia. 2010; pp 34-41.
5. Otero RM. Approach to the Patient in Shock. Tintinalli EJ. *Tintinalli's Emergency Medicine.* New York: McGrawHill. 2011; 165-172.