



A Child Presented with Clitoromegaly in Context with Neurofibromatosis Type 1

Zeindine Sirena* and Al Ebrahim Asad

Department of Pediatrics, General Authority for Pediatric Hospital, Syria

Abstract

Neurofibromatosis type 1, also called Von Recklinghausen disease is a genetic disorder characterized by the development of multiple benign tumors affecting the skin and nervous system. It is a genetic disease with a prevalence of one case in 3,000 births. The cause of VRD is a genetic mutation. In half of all cases of NF1, the faulty gene is passed from a parent to their child. Clitoromegaly presenting in childhood can be congenital or acquired. Non-hormonal causes like NF1, epidermoid cysts, tumor syndromes have been reported. Clitoris enlargement is a frequently seen congenital malformation, but acquired clitoral enlargement is rarely detected. While most cases of VRD are the result of a genetic mutation in the neurofibromin gene, there are also acquired cases due to spontaneous mutations. The pathological alterations behind it begin in the embryonic period, prior to differentiation of the neural crest. We report a case of 6.5 year-old-female admitted for clitoromegaly and an apparent deformity of the genital organs. The girl has been diagnosed with clitoromegaly in the context of NF1 Disease. This patient was successfully treated by clitoroplasty. The biopsied clitoral tissue was sent to pathology and revealed plexiform neurofibroma.

Keywords: NF1; Von Recklinghausen disease; Clitoromegaly; Clitoroplasty; Child

Introduction

NF1 or Von Recklinghausen disease is an autosomal dominant disorder with a basic defect in the embryonic neural crest cells. The plexiform neurofibroma is a diffuse, elongated fibroma along the course of a nerve, frequently involving the trigeminal or upper cervical nerves and usually noticeable within the first 2 years of life [1]. Beginning in early childhood, patients with NF1 have multiple café-au-lait spots, which are flat patches on the skin that are darker than the surrounding area. These spots increase in size and number as the individual grows older. Axillary and groin freckles typically develop later in childhood [2]. We report an unusual case of a plexiform neurofibroma with clitoromegaly in a 6.5 years-old child in context with NF1 [3].

Case Presentation

A 6.5 year-old-girl presented with external genital organs deformity, gradual enlargement of the clitoris and recurrent abdominal pain in the last years. The mother mentioned a history of recurrent diarrhea episodes and underwent a medical consultation to rule out celiac disease which was then excluded by investigations.

In addition, the mother mentioned that her daughter experienced gradual appearance of hyperpigmented lesions on trunk and a gradual enlargement in clitoris during the last years and when asking the mother about familial diseases she mentioned a case of Von Recklinghausen in a 3rd degree relative. The spiritual-kinesthetic development is normal Birth conditions are normal: Weight 20 kg (0 standard deviation), Height 120.5 cm (0 standard deviation). Height for age growth is within normal. Otherwise, the child girl is in good health.

Ophthalmological status

Ophthalmic examination with slit lamp is normal. Visual examination is normal with visual ability 10/10 in both sides with absence of Lisch nodules post Slit-lamp examination.

Physical examination

Dermatological status: 8-9 Café au lait patches (size 1 cm to 2 cm) on trunk, multiple freckles on axillary, trunk and inguinal region. No symptoms of hyperandrogenism. The bone age matches the clinical one lab and imaging studies, histological findings and consultations. The standard laboratory tests values were in the normal range with the only exception of high levels of DHEA

OPEN ACCESS

*Correspondence:

Zeindine Sirena, Department of Pediatrics, General Authority for Pediatric Hospital, Damascus, Syria,
Tel: +963-0988667490;
E-mail: dr.sirena2018@outlook.com

Received Date: 11 Dec 2020

Accepted Date: 28 Dec 2020

Published Date: 04 Jan 2021

Citation:

Sirena Z, Asad AE. A Child Presented with Clitoromegaly in Context with Neurofibromatosis Type 1. *Ann Clin Case Rep.* 2021; 6: 1904.

ISSN: 2474-1655

Copyright © 2021 Zeindine Sirena.

This is an open access article distributed under the Creative Commons Attribution License, which permits unrestricted use, distribution, and reproduction in any medium, provided the original work is properly cited.

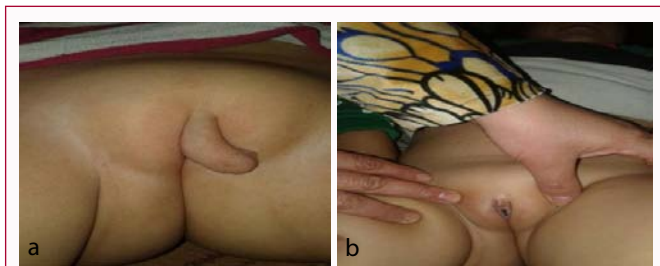

Figure 1: a) Clitoromegaly before surgery b) after clitoroplasty.

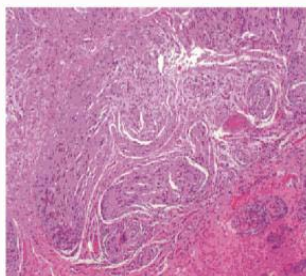


Figure 2: Plexiform neurofibroma.

(52.91 µg/dl). Hand X-ray photography was within the normal too. Abdominopelvic ultrasound was done and showed normal internal genital organs. The histological result revealed plexiform neurofibroma.

Discussion

Von Recklinghausen disease is a multisystem disorder affecting approximately 1 in 3000 people in South East Wales. The symptoms [4] usually appear in childhood and progress with time, and the criteria of VRD are (Figure 1 and 2):

- Family history of NF.
- Six or more café- au-lait patches which are hyper pigmented lesions in different sizes and shapes mainly on trunk.
- Two or more Freckles in the axillary or inguinal area.
- Lisch nodules which are hamartomas of the iris and they are best diagnosed with slit-lamp examination.
- Cutaneous Neurofibromas that may not appear till puberty and increase in number and size with age.
- Plexiform neurofibromas which are tumors affecting the nerving bundles.
- Optic nerve tumors that may affect vision.

Neurofibromatosis type 1 represents a major risk factor for development of malignancy, particularly malignant peripheral nerve sheath tumors, optic gliomas, and leukemia [2].

Tumors can be treated by several methods, including: [4]

- Laparoscopic removal of cancerous tumors

- Surgery for removal of tumors affecting the nerves
- Radiation therapy
- Chemotherapy

Overall, prognosis is good but significant morbidity is common [5]. In our case, the patient complained of clitoromegaly since birth with gradual enlargement with years and gradual appearance of multiple café-au-lait patches and multiple freckles on trunk, and a positive family history of NF1. The patient was successfully underwent clitoroplasty by preserving the glans of the clitoris and neurovascular bundles [1], and the excised tissue was sent to pathology. She was followed up after the operation; there was no early or late post-operative complication [6,7].

Conclusion

NF1 is a multisystem disorder requiring management by multiple disciplines, often coordinated through a primary care physician or a geneticist. The goal of clitoroplasty is to reduce the size of the genital tubercle to give a feminine appearance without compromising future sexual function. After reviewing this case, we recommend that the management of a clitoral neurofibroma consists of surgical excision with all attempts to preserve the clitoris and its adjacent neurovascular structures without compromising future sexual function.

Acknowledgement

I would like to thank Professor Asad al Ebrahim for his help and support throughout this work.

Statement of Ethics

Informed consent was taken for this research. Our study ethical aspects were reviewed and approved by Damascus University, Deanship, Damascus, Syria.

Author Contributions

Zeindine Sirena, Medical Student: Interpretation and wrote the manuscript, Al Ebrahim Asad, MD: Examined the patient and reviewed the manuscript.

References

1. Barker J, Bleiker TO, Chalmers R, Creamer D. Neurofibromatosis type 1. Rook Medical Textbook of Dermatology. 9th Ed. Wiley; 2016.
2. Chouaib S, Mahmoud B, Smain AY, Zineddine S. Neurofibromatosis type 1. J Childhood Developmental Disord. 2016;2(3):20.
3. Meenal G, Vincent H, Abhishek S, Duong Tu, Yemi AF, Lefkothea PK. Persistent progressive clitoromegaly is not always hormonal. Oxford academic J. 2020;4(Suppl 1):A600.
4. Steve K. Von Recklinghausen's Disease (Neurofibromatosis 1). Healthline. 2017.
5. Pr Eric Legius. Neurofibromatosis type 1. Orpha net Report Series. 2020.
6. Neha RM, Earl YC. Clitoroplasty. ELSEVIER J. 2018.
7. Bilommi R, Drajat D. Case report: Clitoroplasty in neurofibromatosis presenting as clitoromegaly. J Pediatr Surg Case Rep. 2015;3(5):201-3.